

Teška kolestaza kod novorođenčeta s PiZZ-genotipom alfa-1-antitripsina – prikaz slučaja

Severe cholestasis in a newborn with PiZZ alpha-1-antitrypsin genotype – A case report

Marijana Žirović¹, Andrea Tešija Kuna¹, Nora Nikolac¹, Mario Štefanović¹, Elizabeta Topić¹, Orjena Žaja-Franulović², Zvonimir Jurčić²

¹Klinički zavod za kemiju, Klinička bolnica „Sestre milosrdnice“, Zagreb

¹University Department of Chemistry, Sestre milosrdnice University Hospital, Zagreb, Croatia

²Klinika za dječje bolesti, Klinička bolnica „Sestre milosrdnice“, Zagreb

²University Department of Pediatrics, Sestre milosrdnice University Hospital, Zagreb, Croatia

Uvod

Neonatalna kolestaza definira se kao opstrukcija žučnih vodova uzrokovana strukturnim ili funkcionalnim anomalijama hepatobilijarnog sustava. Neonatalna kolestaza može biti intrahepatična ili ekstrahepatična. Kod djece se kolestaza pojavljuje sa žuticom, tamnom mokraćom, aholičnom stolicom i hepatomegalijom (1). Do intrahepatične kolestaze kod novorođenčadi, između ostalog, može dovesti i nedostatak α_1 -antitripsina (AAT). Nedostatak AAT je jedan od najčešćih nasljednih bolesti jetre koja dovodi do transplantacije jetre kod djece (2).

AAT je glikoprotein, inhibitor serinskih proteaza (elastaze, katepsina G i proteinaze 3). AAT najvećim dijelom izlučuju hepatociti, a manje alveolarni makrofagi i monociti (3). Gen za AAT koji je lociran na 14. kromosomu vrlo je polimorfan i do sada je već opisano preko 100 mutacija tog gena (4).

Fenotipovi AAT razlikuju se u sustavu proteaznog inhibitora (Pi) prema elektroforetskoj pokretljivosti i koncentraciji AAT u plazmi. Najčešći, normalan fenotip PiM srednje je elektroforetske pokretljivosti s normalnom koncentracijom AAT u serumu. Najčešći deficitarni oblici su PiZ i PiS koje karakterizira snižena koncentracija AAT u serumu te mala (S) ili vrlo mala (Z) brzina elektroforetske migracije (5).

Kod PiZZ koncentracija AAT u serumu je snižena na 15%, a kod homozigota za PiSS na 60% vrijednosti normalne koncentracije. Fenotip PiSZ smanjuje koncentraciju AAT u serumu na 30–35% od normalnih vrijednosti (6).

Nedostatak AAT se kod odraslih klinički očituje kao plućni emfizem, kronični bronhitis i astma, dok djeca imaju dru-

Introduction

Neonatal cholestasis is defined as obstruction of bile flow mostly caused by structural or functional anomaly of hepatobiliary tract. Neonatal cholestasis could be intrahepatic or extrahepatic. Infants with cholestasis present with jaundice, dark urine, acholic stools and hepatomegaly (1). Intrahepatic disorder associated with cholestasis in a newborn is, among others, α_1 -antitrypsin (AAT) deficiency, one of the most common hereditary liver diseases leading to liver transplantation in children (2).

AAT is a glycoprotein, inhibitor of serine proteases (elastase, cathepsin G and proteinase 3) that is mostly secreted by hepatocytes and to a lesser extent by alveolar macrophages and monocytes (3). The AAT gene located on chromosome 14 is very polymorphic with over 100 mutations already described (4).

The AAT phenotype variants are categorized by their electrophoretic mobility and serum concentrations to protease inhibitor (Pi) system. The most common, normal variant is middle migrating PiM allele characterized by normal AAT serum concentrations. The most frequent deficient variants are PiZ and PiS, characterized by reduced AAT serum concentrations and slow (S) or very slow (Z) migration velocity (5).

PiZZ and PiSS homozygous genotypes reduce AAT serum level to 15% and 60% of normal serum concentrations, respectively. PiSZ phenotype shows reduction of the AAT serum concentration to 30–35% of the normal value (6).

AAT deficiency could clinically present as pulmonary emphysema, chronic bronchitis and asthma in elderly, but infants have other symptoms. In infancy and childhood,

Pristiglo: 19. travnja 2007.

Prihvaćeno: 25. rujna 2007.

Received: April 19, 2007

Accepted: September 25, 2007

gačije simptome. Kod novorođenčadi i djece nedostatak AAT može dovesti do produžene opstruktivne žutice s teškim poremećajem funkcije jetre koja kod otprilike 1–2% djece s nedostatkom AAT može dovesti i do smrtonosne ciroze (7-9).

Zanimljivo je da samo 10–15% djece s genotipom PiZZ razvija kliničku kolestazu u djetinjstvu s različitim tijekom bolesti (10).

U ovom radu prikazujemo slučaj novorođenčeta s teškom intrahepatičnom kolestazom povezanom s nedostatkom α_1 -antitripsina.

Prikaz slučaja

Novorođenče staro 15 dana (tjelesne visine 0,61 m i težine 5,1 kg) primljeno je u Gastroenterološki odjel Klinike za dječje bolesti u Kliničkoj bolnici "Sestre milosrdnice" zbog blijede stolice i sumnje na kolestazu. Majka je primijetila blijedu stolicu već kod novorođenčeta starog 9 dana. Novorođenče nije imalo vidljivu žuticu, ali mokraća je bila tamno obojena. Dijete je hranjeno majčinim mlijekom uz dodatak komercijalne hrane.

Provjerom bolesnikove anamneze ustanovljeno je da je dječak rođen carskim rezom po izboru majke u 38. gestacijskom tjednu kao treće dijete. Nakon rođenja dječak je težio 2580 g, a bio je dugačak 48 cm. Nakon sedam dana otpušten je iz rodilišta s težinom 2390 g. Ustanovljeno je da su dječakovi roditelji i dvije sestre zdravi.

Prilikom primitka u Kliniku za dječje bolesti, novorođenče je naizgled bilo zdravo, dobrog općeg stanja. Zbog sumnje na opstrukciju žučnih vodova dječaku su načinjene biokemijske, hematološke i koagulacijske pretrage, kao i ultrazvučni pregled te scintigrafija s tehnecijem (engl. *Tc-99m-hepatic imino diacetic acid*, HIDA).

Od općih biokemijskih pretraga dječaku su u serumu određeni: ukupni i konjugirani bilirubin, AST, ALT, GGT, ALP, 5'-NU, žučne kiseline, α_1 -antitripsin, α -fetoprotein, ukupni kolesterol, HDL- i LDL-kolesterol, trigliceridi, CRP, te imunoglobulini IgG, IgA i IgM. Uz gore navedene pretrage, određena mu je i sedimentacija eritrocita, diferencijalna krvna slika, vrijeme krvarenja i zgrušavanja, protrombinsko vrijeme, kao i fibrinogen. U tablici 1 prikazane su samo izmjerene vrijednosti izvan referentnih intervala, dok su ostale pretrage bile unutar granica referentnih intervala.

Povišene koncentracije ukupnog i konjugiranog bilirubina prisutne su već kod novorođenčeta starog 15 dana. Katalitička aktivnost GGT također je povišena. Aktivnosti drugih jetrenih enzima (AST, ALT i ALP) u granicama su referentnih intervala. Koncentracija žučnih kiselina bila je izrazito povišena. Zbog snižene koncentracije AAT u serumu načinjena je genotipizacija i fenotipizacija AAT (11, 12). Kod dječaka je pronađen genotip PiZZ. Koncentracija konjugiranog bilirubina u serumu novorođenčeta bila je također povišena, zbog čega je načinjena genotipizacija

AAT deficiency can cause prolonged obstructive jaundice with severe liver dysfunction leading to lethal cirrhosis in 1–2% of deficient infants (7-9).

Intriguingly, only 10–15% PiZZ individuals develop clinical cholestasis in childhood with diverse subsequent course (10).

In this report, we present a case of a newborn with severe intrahepatic cholestasis associated with α_1 -antitrypsin deficiency.

Case report

A 15-day-old male newborn (body length 0.61 m, body weight 5.1 kg) was admitted to the Gastroenterology ward of the Pediatrics Department, Sestre milosrdnice University Hospital, due to pale stools and suspected cholestasis. The mother had noticed acholic stools when the boy was 9 days old. The jaundice was not present although the urine was dark colored. The newborn was breastfed with a commercial food supplementation.

The patient's personal history revealed that he was born in the 38th gestational week via elective Cesarean section as a third-born child. His birth weight was 2580 g and birth length 48 cm. After 7 days he was released from the maternity hospital with the total weight of 2390 g. The newborn's parents and two sisters were healthy.

Physical examination on admission to the Pediatrics Department showed no particularities, with stable general condition. Biochemical, hematological and coagulation tests, as well as ultrasound examination and Technetium 99m-hepatic imino diacetic acid (HIDA) scintigraphy were performed for the exclusion of bile duct anomalies.

The general biochemical parameters determined were: total and conjugated bilirubin, AST, ALT, GGT, ALP, 5'-NU, bile acids, α_1 -antitrypsin, α -fetoprotein, total cholesterol, LDL and HDL cholesterol, triglycerides, CRP, IgG, IgA and IgM immunoglobulins in serum. Erythrocyte sedimentation rate (ESR), differential blood count, bleeding time, clotting time, prothrombin time (PT) and fibrinogen were also determined. Table 1 shows only the values which were not in the reference ranges while other measured parameters were normal.

Concentrations of total and conjugated bilirubin were increased already in the 15-day-old newborn. GGT activity was also increased. Activities of other liver enzymes (AST, ALT and ALP) were normal. The concentration of the newborn's bile acids was extremely increased. Due to decreased AAT serum concentration, genotyping and phenotyping were performed (11, 12) and revealed AAT deficiency in the PiZZ genotype. Due to increased concentration of unconjugated bilirubin in the newborn's serum, the genotyping for Gilbert's disease was performed but the polymorphism was not found.

TABLICA 1. Biokemijski parametri izmjereni kod dječaka starosti 15 dana i 4 mjeseca.**TABLE 1.** Biochemical parameters measured in the infant aged 15 days and 4 months.

Analyte	Measured values		Reference range	Units
	Infant's age			
	15 days	4 months		
Total bilirubin	83.1	94.6	3.0–17.0	μmol/L
Conjugated bilirubin	29.5	39.3	< 2.0	μmol/L
AST	48	153	26–75	U/L 37 °C
ALT	29	159	11–46	U/L 37 °C
GGT	171	1790	15–132	U/L 37 °C
ALP	256	1010	25–500	U/L 37 °C
Bile acids	106.3	151.3	10.0	μmol/L
5'-nucleotidase	3.8	54.1	< 9.0	U/L 37 °C
α ₁ -antitrypsin	0.46		1.3–2.4	g/L

UDP glukuronozil-transferaze (UGT1A1) zbog sumnje na Gilbertov sindrom, ali polimorfizam nije nađen.

Dva scintigrama abdomena načinjena su 24 sata nakon uvođenja radioaktivne tvari. Druga HIDA načinjena je za potvrđivanje rezultata dobivenih prvom scintigrafijom. U oba slučaja radioaktivna tvar normalno se nakupljala u jetri, ali prolaz u crijeva nije zabilježen. Tom pretragom potvrđena je sumnja na tešku intrahepatičnu kolestazu.

Nakon uvođenja terapije za bolest jetre, novorođenče je otpušteno iz bolnice. Četiri mjeseca kasnije dječak je ponovno primljen u bolnicu bez znakova poboljšanja stanja. Katalitičke aktivnosti svih jetrenih enzima (GGT, AST, ALT i ALP) bile su izrazito povišene. Ultrazvukom jetre i abdomena nije primijećena promjena prvobitnog stanja, a jetra je bila normalne veličine.

Kada se otkrilo da novorođenče ima sniženu koncentraciju AAT u serumu, dječakovim roditeljima također je izmjerena koncentracija AAT u serumu te im je načinjena fenotipizacija i genotipizacija AAT. Majci je izmjerena koncentracija AAT u serumu od 1,01 g/L (referentni interval 1,30–3,00 g/L) s genotipom PiSZ. Kod oca je koncentracija AAT u serumu iznosila 1,50 g/L uz genotip PiMZ.

Za određivanje genotipa AAT načinjene su dvije reakcije umnažanja (S PCR i Z PCR) s dva para početnica. Svaka PCR-reakcija ima svoje produkte (S i Z produkte), a kombinacijom rezultata s dva gela očitani su konačni genotip (isti aleli u obje PCR-reakcije određuju genotip). Rezultati genotipizacije na gelu prikazani su na slici 1.

Rasprava

Prikazani slučaj do sada je najteži neonatalni slučaj intrahepatične kolestaze uzrokovane nedostatkom α₁-antitripsina u Kliničkoj bolnici "Sestre milosrdnice". U razdoblju

Two HIDA abdomen scintigrams were done 24 hours after initiation of radioactive substance. The second one was done to confirm first results. In both cases the radioactive substance was normally accumulated in the liver, but without passage to the intestine. These examinations confirmed suspicion of severe intrahepatic cholestasis.

The newborn was released from the hospital after initiation of therapy for cholestatic liver disease. Four months later he was admitted again due to no signs of improvement but with exacerbation of condition. Activities of all liver enzymes (GGT, AST, ALT and ALP) were significantly above the upper reference limit.

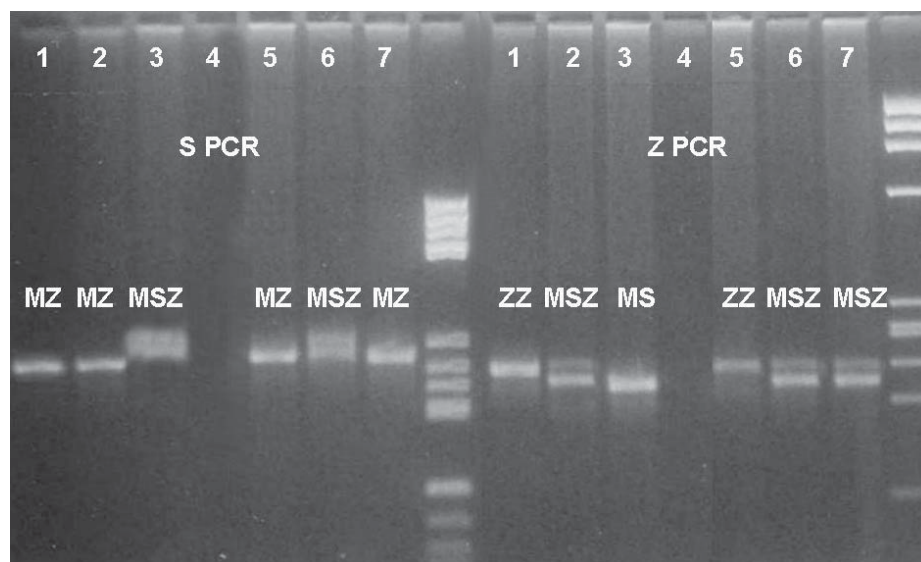
The liver and spleen ultrasound examination showed no particularities and the size of the liver was normal.

After decreased AAT serum concentration was revealed in the newborn, AAT concentrations were also measured in the newborn's parents, with results of 1.01 g/L for mother and 1.50 g/L for father (reference range 1.30–3.00 g/L). Also, AAT genotyping and phenotyping were performed. The mother was found to have PiSZ genotype and the father had PiMZ genotype.

For the AAT genotyping, two PCRs (S PCR and Z PCR) were performed with two sets of primers. Each PCR had its own products (S and Z products). By combining those results (the same alleles in both PCRs defining genotype) the final genotypes for the infant and his parents were read. The scanned picture of the gel is shown in Figure 1.

Discussion

The above presented case has been the most severe neonatal case of intrahepatic cholestasis caused by AAT deficiency in our hospital. In the period since 1977, approxi-



SLIKA 1. Prikaz rezultata S-PCR i Z-PCR-reakcije za genotipizaciju α_1 -antitripsina

LEGENDA:

- | | |
|-----------------------------|--------------------------------------|
| 1 – ZZ kontrola | 5 – novorođenče – ZZ |
| 2 – MZ kontrola | 6 – majka – SZ |
| 3 – MM kontrola | 7 – otac – MZ |
| 4 – destilirana voda | M – biljeg molekularne težine |

FIGURE 1. AAT genotyping results of S- and Z-PCR

LEGEND:

- | | |
|----------------------------|------------------------------------|
| 1 – ZZ control | 5 – newborn – ZZ |
| 2 – MZ control | 6 – mother – SZ |
| 3 – MM control | 7 – father – MZ |
| 4 – distilled water | M – molecular weight marker |

od 1977. godine do danas u KB "Sestre milosrdnice" opisano je oko 30 slučajeva nedostatka AAT kod homozigota ili heterozigota. Prvi slučaj nedostatka AAT u našoj bolnici opisan je već 1977. godine (13). Prije nekoliko godina objavljeno je i istraživanje o genotipizaciji AAT u nekoliko hrvatskih obitelji (14,15).

Koncentracija AAT u serumu novorođenčeta bila je snižena na 30–35% od donje granice referentnog raspona, što je više od očekivane koncentracije kod genotipa PiZZ. Razlog je vjerojatno u akutnom upalnom odgovoru kod kojeg raste koncentracija AAT.

Već je izvještavano o slučajevima djece koja su preminula zbog ciroze uzrokovane nedostatkom AAT u dobi do 7 godina (16). U našoj bolnici, opisani slučaj prvi je takve težine. Kod dječaka opisanog u ovom prikazu slučaja oštećenje jetre je uznapredovalo, što zahtijeva transplantaciju jetre.

Kod majke je pronađen genotip PiSZ α_1 -antitripsina. Zanimljivo je da je to prvi slučaj od ukupno 152 (0,66%) određena genotipa s genotipom PiSZ otkriven u našoj bolnici u 7 godina otkako se određuje genotip, odnosno prvi put u 11 godina fenotipizacije.

Slučaj teške kolestaze vrlo je rijedak i tek 6% djece razvija takav klinički tijek bolesti. Oko 15% bolesnika sa žuticom uzrokovanom kolestazom razvija mladenačku cirozu (17).

mately 30 cases of homozygous and heterozygous AAT deficiency have been observed in our clinical hospital. The first case of AAT deficiency in the hospital was described in 1977 (13). A few years ago, studies about genotyping of AAT in Croatian families were published, also from our hospital (14, 15).

The newborn's AAT serum concentration was decreased to 30–35% of the reference value, which is a higher level than expected in PiZZ genotype. The reason could be the acute inflammatory response which causes a rise in the AAT concentration.

Cases of children that died at 7 years of age due to cirrhosis caused by AAT deficiency have already been reported (16) but in our hospital this is the first case of such a severe presentation of AAT deficiency. The child presented in this case report is currently affected by liver damage and needs a liver transplantation.

An interesting finding in this case was the mother's PiSZ genotype. During 7 years of genotyping and 11 years of phenotyping, this was the first time in 152 cases (0.66 %) with suspected AAT deficiency that we found PiSZ genotype.

This case of cholestasis with jaundice is a very rare occurrence and only 6% of infants develop such clinical disease. In approximately 15% of patients, cholestatic jaundice progresses to juvenile cirrhosis (17).

Zaključak

Kod dječaka je potvrđena teška intrahepatična kolestaza povezana s nedostatkom α_1 -antitripsina. Genotipizacijom i fenotipizacijom α_1 -antitripsina kod novorođenčeta i njegovih roditelja pronađen je genotip PiZZ kod dječaka, PiSZ kod njegove majke te genotip PiMZ kod oca. Genotip PiSZ je vrlo rijedak i otkriven je prvi put u 7 godina naše prakse određivanja genotipa, odnosno prvi put u 11 godina fenotipizacije.

Adresa za dopisivanje:

Marijana Žirović
Klinički zavod za kemiju
Klinička bolnica „Sestre milosrdnice“
Vinogradska 29
10000 Zagreb
Hrvatska
e-pošta: mzirovic@gmail.com
tel: +385 1 3787 405

Conclusion

Severe intrahepatic cholestasis associated with alpha-1-antitrypsin deficiency was confirmed in a newborn. Genotyping and phenotyping of the newborn and his parents revealed PiZZ genotype in the newborn, PiSZ genotype in his mother and PiMZ in his father. PiSZ genotype is a very rare AAT genotype which was detected in our 7-years of genotyping and 11 years of phenotyping for the first time.

Corresponding author:

Marijana Žirović
University Department of Chemistry
Sestre milosrdnice University Hospital
Vinogradska 29
10000 Zagreb
Croatia
e-mail: mzirovic@gmail.com
phone: +385 1 3787 405

Literatura/References

- Balistreri WE, Schubert WK. Liver disease in infancy and childhood. In: Schiff L, Schiff ER, eds. *Diseases of the liver*. Philadelphia: JB Lippincott; 1993.
- Steiner SJ, Gupta SK, Croffie JM, Fitzgerald JF. Serum levels of α_1 -antitrypsin predict phenotypic expression of the α_1 -antitrypsin. *Digestive diseases and Sciences* 2003;48:1793-6.
- Perlmutter DH. Alpha-1-antitrypsin deficiency. In: Schiff ER, Sorrell MF, Maddrey WC, eds. *Schiff's Disease of Liver*. 9. ed. Philadelphia: Lippincott-Raven, 2002;1206-29.
- American Thoracic Society Documents: Statement on the Care of the Child with Chronic Lung Disease of Infancy and Childhood. *Am J Respir Crit Care Med* 2003;168:356-96.
- Canva V, Piotte S, Aubert JP, Porchet N, Lecomte-Houcke M, Huet G et al. Heterozygous M3Mmalton alpha1-antitrypsin deficiency associated with end-stage liver disease: case report and review. *Clin Chem* 2001;47:1490-6.
- Teckman JH, Lindblad D. Alpha-1-antitrypsin deficiency: diagnosis, pathophysiology and management. *Curr Gastroenterol Rep* 2006;8:14-20.
- Perlmutter DH, Brodsky JL, Balistreri WF, Trapnell BC. Molecular Pathogenesis of alpha-1-antitrypsin deficiency-associated liver disease: A meeting review. *Hepatology* 2007;45:1313-23.
- Richmond RJ, Zellner KM. α_1 -Antitrypsin deficiency: Incidence and implications. *Dimens Crit Care Nurs* 2005;24:255-60.
- Perlmutter DH. Pathogenesis of chronic liver injury and hepatocellular carcinoma in alpha-1-antitrypsin deficiency. *Pediatr Res* 2006;60:233-8.
- Hinds R, Hadchouel A, Shanmugham NP, Al-Hussaini A, Chambers S, Cheeseman P et al. Variable degree of liver involvement in siblings with PiZZ alpha-1-antitrypsin deficiency-related liver disease. *J Pediatr Gastroenterol Nutr* 2006;43:136-8.
- Jeppsson JO, Franzen B. Typing of genetic variants of alpha 1-antitrypsin by electrofocusing. *Clin Chem* 1982;28:219-25.
- Cox DW, Billingsley GD, Siewertsen MA. α_1 -antitrypsin. In: Hommes FA, ed. *Techniques in diagnostic human biochemical genetics: a laboratory manual*. New York: Alan R Liss Inc, 1991;473-89.
- Jurčić Z, Dogan K, Rudar D, Buneta L. Genetski hepatitis: prikaz bolesnika s alfa, antitripsin deficitom. *Zbornik radova, III kongres gastroenterologa Jugoslavije, Portorož, 14.-17. rujna, 1977*;331-4.
- Žuntar I, Topić E, Jurčić Z, Zubčić A. Genotyping of alpha-1-antitrypsin in family studies. *Biochemia Medica* 2000;3-4:129-35.
- Žuntar I, Topić E, Jurčić Z. Genotyping of alpha-1-antitrypsin in deficient families in Croatia. *Acta Pharm* 2001;51:11-9.
- Primhak RA, Tanner MS. Alpha-1 antitrypsin deficiency. *Arch Dis Child* 2001;85:2-5.
- Crowther DC, Belorgey D, Miranda E, Kinghorn KJ, Sharp LK, Lomas DA. Practical genetics: alpha-1-antitrypsin deficiency and the serpinopathies. *Eur J Hum Genet* 2004;12:167-72.